

Inferior mandibular border osteotomy after reduction genioplasty in two cases: a new technique

Nima Sadeghi^{1*} 

¹ Maxillofacial surgeon, private practice, Tehran, Iran.

*Corresponding Author: Maxillofacial surgeon, private practice, Tehran, Iran. Email: sadeghinima91@gmail.com.

Received 2023-11-28; Accepted 2023-12-22; Online Published 2024-03-01

Abstract

The chin plays an important role in aesthetic harmony, especially in the lower third of the face, its prominence and vertical length have a great impact on the profile of the face. Bone genioplasty is a functional surgery that provides the possibility of correcting chin defects in three horizontal, vertical and transverse levels by sliding, jumping, reduction and centralizing methods. Today, a V-shaped elongated chin is very desirable. The final result of the surgeries is always accompanied by a step that creates an additional angle in the jaw and overshadows the V-shaped chin surgery and makes the patient look older. In the present work, a new modified method based on inferior mandibular border osteotomy reduction of distal bone is presented, based on which the step created in the old methods is replaced with a gentle angle. For this purpose, a comparison has been made between the old reduction method and the modified method performed on two female patients. In both cases, X-ray radiography, photo slides and general examination of the patient, was utilized for discussion and investigation. The results showed well that the applied method can provide a perfect and very compliant surgery without creating an additional step and angle. In the corrected state, the absence of the angle made the patient's age appear as her own.

Keywords: Reduction genioplasty, long face lip incompetency, chin augmentation, chin prosthesis, chin advancement.

Citation: Sadeghi N. Inferior mandibular border osteotomy after reduction genioplasty in two cases: a new technique . Int J Travel Med Glob Health, 2024;12(1):59-63. doi: 10.30491/IJTMGH.2023.427436.1392.

1. Introduction

Beauty is a concept that depends on the subject's understanding so a specific definition cannot be found. But the proportion of the facial parts and the presence of symmetry in the face are the main criteria for determining the standard in the face¹. In an ideal case, the distance between the hairline of the forehead and the eyebrow is equal to the distance from the eyebrow to the nose and also to the distance from the nose to the end of the chin². Based on this, the face can be divided into three parts, which are divided by the horizontal line and in the area of the eyebrow and under the nose³. The third part of the end of the face, which is from the stomion to the chin, is twice the distance between the stomion and the nose⁴. For a better understanding, Riddle's guide lines or harmony lines are usually used, which connect the most prominent points of the upper and lower lips with the pogonion point, which is located above the chin, in order to determine the desired prominence of the chin⁵. Any change in these proportions and the relationship between

chin and nose affects the balance and coordination of the face⁶. Undoubtedly, the chin is one of the strongest anatomical features that plays a central role in the three-dimensional coordination of the face⁷. Therefore, in the absence of this symmetry, nose or chin surgery is performed to fix the appearance defects or for therapeutic purposes. Although chin surgery is less known than nose surgery, the positive effects of chin surgery help the patient to increase his self-confidence and ultimately improve his quality of life in the long run⁸. Genioplasty is a basic surgical technique, which is performed primarily as a bony procedure and secondarily as an alloplasty method⁹. This method was first introduced by Hofer with an extraoral approach in 1942 and then in 1957 by Trauner and Obwegesser and the intraoral method was presented to correct anomalies in three horizontal, vertical and transverse levels¹⁰. Generally, in genioplasty after surgical osteotomy, the distal bone is freely positioned in the final correction position, which was

previously determined by preoperative analysis. Of course, the general division is based on the specific movement of the distal part, which includes the four main categories of sliding, jumping, reducing, and centralizing. In the reduction method, it moves vertically and makes the chin shorter. In the central method, the front part of the chin is placed in the correct place in the horizontal direction¹¹. The sliding method is presented based on the oblique osteotomy of the symphysis and considering the position of the chin¹². Despite the good efficiency of this method, after the patient's complete recovery, it creates a stepped slope in the profile, which is not aesthetically attractive, so it is sometimes suggested to add bone graft to fill the gap between the two steps¹³. D. R. Jones et al showed that bifurcation overlap genioplasty, which often results in overcorrection of the chin bulge with anterior ridges and deeper labial folds, is considered counter-esthetic, especially in women¹⁴. Because women prefer a narrower chin with less prominence, which has a single-point reflection¹⁵. In the work of S.O. Keyhan and et al., the zigzag genioplasty method was presented for the three-dimensional reduction of the chin. In this method, the cutting angle was determined based on the vertical and transverse displacement, the height and width of the mandibular symphysis, the size of the bone fragments, the need for conventional or long reduction of the mandible, the position of the anterior teeth of the mandible, and the symmetry of the skull bone before the operation¹⁶.

Combining methods usually leads to better results. Usually, during the evaluation of patients, surgeons pay more attention to the lack of chin protrusion, while sometimes patients have macrogenes and need to make the chin shorter, which usually is rarely offered, and one of the main reasons for this can be the lack of technical equipment or the lack of Knowledge enough pointed out¹⁷.

The present work has been used through sliding genioplasty and the chin reduction method both horizontally and vertically to correct the chin, which has led to the introduction of a new method, the results of which are very acceptable to the surgeon in terms of aesthetics and time of mandibular margin recovery. This surgery can be used especially for patients with long and wide chin.

2. Case presentation

In 2022 a female patient was referred to the author to undergo double jaw surgery or chin reduction. The surgical method was intra-oral, lateral and posteroanterior

cephalometric diagnostic analyses were used to evaluate the patient before the surgery. Examinations showed defective occlusion class I because of vertical maxillary excess can show long gamine and lip incompetency in the patient, which required double jaw surgery. The surgery was performed under general anaesthesia and the patient was placed in the supine position. Intubation was done through the nose to create an airway between the jaw and the hard tissue. The surgery started after reducing the maxilla by 5 mm and advancement of the mandible using bilateral sagittal split osteotomy (BSSO). In more detail, first an incision was made in the retromolar pad of the soft tissue in the lower jaw, then the sagittal mandible was performed. After that, the maxilla was reduced by 5 mm with a vestibular cut from teeth 4 to 4 and then with a Defort maxilla cut. In order to improve breathing, inferior turbinate patient was removed and the caudal septum was shortened by 5 mm, which was considered to prevent deviation of the nasal septum. After that, the maxilla and mandible were placed in the right position by screws and plates. After cutting the soft tissue, the genioplasty was cut in the area between the 4th and 4th teeth in the vestibular depth. The chin was brought forward by about 7 mm and shortened by 5 mm and fixed by 1 place. Then, the step-like area between the border of the mandible and the chin segment was removed by a saw and a 2 mm osteotomy. The area between the bones was filled with allograft of the Botiss company of Germany. After that, at the end, suturing was done in the double layer of the mentalis muscle and the mucous membrane, respectively, by three zero and four zero Vicryl thread.

Inter maxillary fixation (IMF) made the bone segments stable and improved the osteotomy. IMF was placed using a screw in the anterior and upper teeth area. The attached screw was attached to the upper and lower jaw by a wire to keep the occlusion stable. A 3 cm mucosal incision was made on the lower vestibular fornix and the mentalist muscle was also cut. Then, the lower left side was placed by atraumatic subperiosteal dissection with the muscle line and soft tissues in the lower part of the symphysis to ensure the vascular supply of the bony part under surgery. The middle of the chin was marked by placing a screw to facilitate its subsequent position change. An osteotomy was performed using piezosurgery with a short angle tip. The osteotomy lines started medially and extended laterally about 5 mm below the foramen to ensure that the dental roots were protected. The first ostomy line was a monocortical osteotomy that allowed the integrity of the tongue cortex to be preserved.

About 3 mm lower than the complete osteotomy was performed in the second cortex and for the mobility of the chin. The osteotomized chin was attached using a bone anchor screw as a traction point and placed in front of the bone. After shortening the chin routine and moving it to the front and a higher position, the chin profile was corrected. After fixing in the new place, the bone cut that included the bony stapes was cut by a saw (specifications) to a size of 1 cm as Throw and Throw, and separated from the mandible by a 2 mm acetoma, which resulted in uniform connection and step removal was created. Therefore, the area of the lower board became uniform.

Internal fixation and neutralization of tensile forces with suprahyoid muscles are ensured. The osteosynthesis of the fragment was done using two titanium plates that were made by the surgeon during the operation and the integration of the mentalis muscle with Vicryl 4 suture to prevent any angle change and the mucosal layer was sutured with fast absorbable suture thread. One day after the operation, X-ray analysis was performed to check the new position of the bone and the stability of the titanium plates. Patients were advised to maintain a soft diet and to rinse their mouths frequently with a saline solution until the first postoperative visit at 1 week. The patient underwent examinations for four weeks after surgery to ensure proper healing of the surgical incisions. Two months after the surgery, an X-ray was taken, which showed complete bone healing and stability of the plates.

3. Discussion

[Figure 1](#) shows the releasing method described in the method section. To separate the bone from the two areas of the mental foramen (A) and the alular process (B), there should be a distance of 5 mm, and the cut with an approximate angle of 120° in this area is done safely and without damaging the jaw nerves.

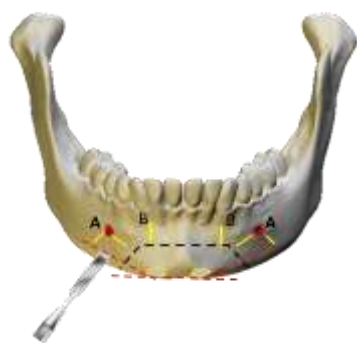

Figure 1. Schematic of bone separation method according to mental foramen (A) and alveolar process (B).

[Figure 2](#) A and B show pictures of lateral cephalometric (Lat Cep) before and after chin symmetry surgery with the old sliding method. Although the surgery has been completely successful, by drawing Riddle's line, the most projecting points of the nose, upper lip, lower lip, and chin can be seen in the same direction, which is proof of the complete correction of the patient's complaint. Also [Figure 2-C](#) the posteroanterior cephalometric (PA Cep) displays the correction of the chin asymmetry. But the point that is marked with a red dashed line in [Figure 2-D](#) for highlighting is the step-like distance of 0.8 cm height, which creates an additional angle in the jaw line. The reduction methods that have been presented so far are bound to create this step.

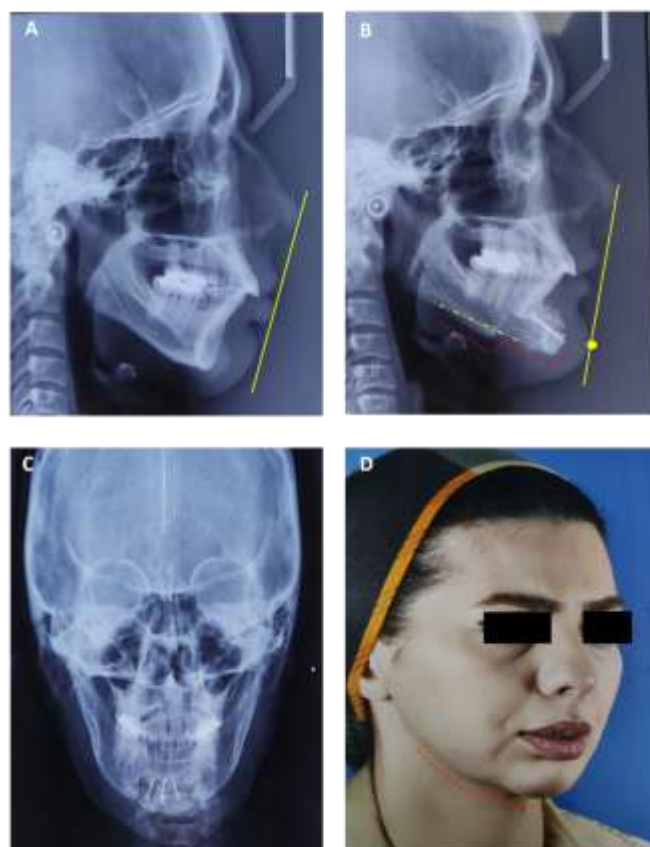


Figure 2. Images of the female patient undergoing surgery with old method. Lat Cep preoperative (A), Lat Cep postoperative after 2 months (B), PA Cep postoperative after 2 months (C), photo slide profile of the same patient (Published with the patient's consent).

The issue becomes more important when we see the photo slide of the post-op patient in [Figure 2-D](#). This step makes the patient look older. Because it is a reminder of the closeness of the skin to the bone, which usually happens in middle age, and this is far from the primary goals of aesthetics. On the other hand, surgery should be done in

such a way that it does not lead to aggravation of symptoms after the patient gets older. The yellow dotted line displayed the discussing area that should be removed to smooth the profile jaw line.

Figure 3 (A and B) shows the photo slides of a female patient with class I malocclusion because of vertical maxillary excess which can show long gamine and lip incompetency. She was operated using the new modified reduction method introduced in this article. As a quick conclusion after the surgery, no additional angle is observed along the jaw line. On the other hand, the general condition of the patient was good during post-water stages and no swelling, infection or additional chronic pain was reported.

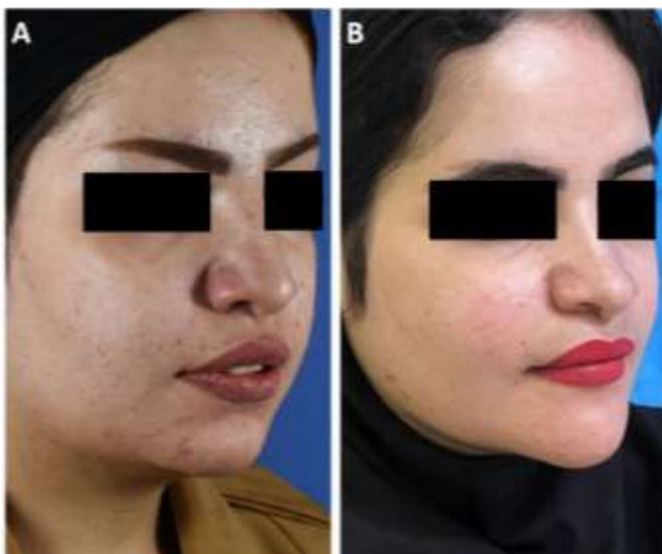

Figure 3. Images of the female patient undergoing surgery with the modified method. preoperative (A) and postoperative after 2 months (B) profile photoslide (Published with the patient's consent).

The profile view of the patient shown by the X-ray images, both Lat and PA Cep is presented in **Figure 4** (A to D). Riddle's lines (**Figure 4- A and B**) confirm the complete correction of the deformity. In addition, the gentle cut does not introduce any additional angles in the jaw line. The PA Cep photos before and after surgery, respectively **Figure 4-C and D**. It shows the symmetry of the chin on the left and right side. Therefore, in addition to removing the deformity, the surgery has also improved the beauty. Due to its ease and effectiveness, this method was also used in several patients, the results of all which were very successful and were associated with complete patient satisfaction. No symptoms of pain or secondary infection were observed in any of them.

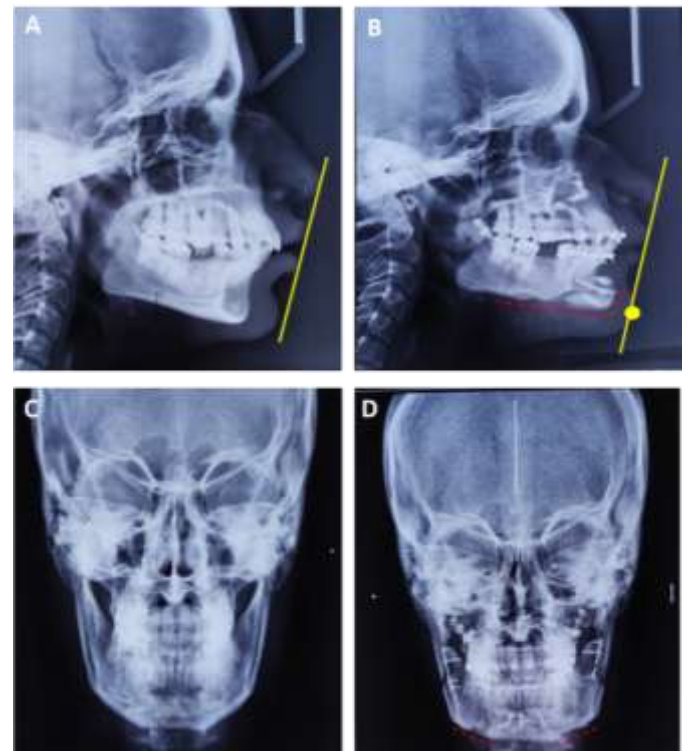


Figure 4. Radiography of the same patient in figure 2 undergoing surgery with modified method. Lat Cep preoperative (A), Lat Cep postoperative after 2 months (B), PA Cep preoperative after 2 months (C), PA Cep postoperative after 2 months (D) (Published with the patient's consent).

This proposed operation method has several advantages such as satisfaction, physician satisfaction, chin movement, bone resorption, and other complications. The chin slides along the oblique sagittal slopes, which increases bony contact and also ensures less deformity or unevenness in the final result. So it is a convenient method for patient with long and wide chin.

4. Conclusion

The main goal of facial surgery is to achieve beauty standards in addition to removing deformities. Genioplasty is a technique that has received much attention from surgeons due to the low rate of side effects, the predictability of the result, and the high level of patient satisfaction. After osteotomy, the distal bone can be freely placed in horizontal, vertical and transverse positions. In all these methods, a step-like part is created by introducing a new angle in the profile of the patient, leading to a distance from the beauty standards because it makes the patient look older. In the present work, a corrective method for sliding reduction surgery is introduced, in which osteotomy with an angle of 120° from the antegonial notch to the foreside of the mandible, which leads to a V-shaped chin structure. No

complications such as hematoma, bleeding, infection or sensory changes were seen in the innervation area by the mandibular branch. The result was also interesting in terms of aesthetics. The soft tissues adapted satisfactorily to the new position. Lower third morphology was aesthetically satisfactory.

Highlights

What Is Already Known?

Setup a new technique for Inferior mandibular border osteotomy after reduction genioplasty.

A new modified method based on inferior mandibular border osteotomy reduction of distal bone.

What Does This Study Add?

The applied method can provide a perfect and very compliant surgery without creating an additional step and angle.

References

1. Fitzpatrick BN. Genioplasty with reference to resorption and the hinge sliding osteotomy. *International Journal of Oral Surgery*. 1974 Jan 1;3(5):247-51. [https://doi.org/10.1016/s0300-9785\(74\)80056-6](https://doi.org/10.1016/s0300-9785(74)80056-6).
2. Niechajev I. Reduction genioplasty for mandibular prognathism and long chin. *Oral and Maxillofacial Surgery*. 2020 Sep; 24:333-41. <https://doi.org/10.1007/s10006-020-00853-8>.
3. Agbaje JO, Gemels B, Salem AS, Anumendem D, Vrielinck L, Politis C. Modified mandibular inferior border sagittal split osteotomy reduces postoperative risk for developing inferior border defects. *Journal of Oral and Maxillofacial Surgery*. 2016 May 1;74(5):1062-e1. <https://doi.org/10.1016/j.joms.2016.01.005>.
4. Chang EW, Lam SM, Karen M, Donlevy JL. Sliding genioplasty for correction of chin abnormalities. *Archives of Facial Plastic Surgery*. 2001 Jan 1;3(1):8-15. <https://doi.org/10.1001/archfacial.qoa00045.8>.
5. Posnick JC, Egolum N, Tremont TJ. Primary mandibular deficiency dentofacial deformities: occlusion and facial aesthetic surgical outcomes. *Journal of Oral and Maxillofacial Surgery*. 2018 Oct 1;76(10):2209-e1. <https://doi.org/10.1016/j.joms.2018.06.009>.
6. Agbaje JO, Gemels B, Salem AS, Anumendem D, Vrielinck L, Politis C. Modified mandibular inferior border sagittal split osteotomy reduces postoperative risk for developing inferior border defects. *Journal of Oral and Maxillofacial Surgery*. 2016 May 1;74(5):1062-e1. <https://doi.org/10.1016/j.joms.2016.01.005>.
7. Maglito F, Sani L, Piloni S, Del Prete GD, Arena A, Committeri U, Salzano G, Califano L, Friscia M. Step-technique genioplasty: A case report. *International Journal of Surgery Case Reports*. 2022 Jun 1; 95:107232. <https://doi.org/10.1016/j.ijscr.2022.107232>.
8. Wyatt WM. Sagittal ramus split osteotomy: literature review and suggested modification of technique. *British journal of oral and maxillofacial surgery*. 1997 Apr 1;35(2):137-41. [https://doi.org/10.1016/s0266-4356\(97\)90691-4](https://doi.org/10.1016/s0266-4356(97)90691-4).
9. Niechajev I. Reduction genioplasty for mandibular prognathism and long chin. *Oral and Maxillofacial Surgery*. 2020 Sep; 24:333-41. <https://doi.org/10.1007/s10006-020-00853-8>.
10. Trauner R, Obwegeser H. The surgical correction of mandibular prognathism and retrognathia with consideration of genioplasty: Part I. Surgical procedures to correct mandibular prognathism and reshaping of the chin. *Oral surgery, oral medicine, oral pathology*. 1957 Jul 1;10(7):677-89. [https://doi.org/10.1016/s0030-4220\(57\)80063-2](https://doi.org/10.1016/s0030-4220(57)80063-2).
11. Tauro DP, Manay RS. The stair step genioplasty: a modification of the oblique sagittal sliding genioplasty. *British Journal of Oral and Maxillofacial Surgery*. 2019 Dec 1;57(10):1163-4. <https://doi.org/10.1016/j.bjoms.2019.09.009>.
12. Ho CT, Huang CS, Lo LJ. Improvement of chin profile after mandibular setback and reduction genioplasty for correction of prognathism and long chin. *Aesthetic plastic surgery*. 2012 Oct;36:1198-206. <https://doi.org/10.1007/s00266-012-9933-y>.
13. Rustemeyer J, Lehmann A. Reduction genioplasty enhances quality of life in female patients with prognathism and maxillary hypoplasia undergoing bimaxillary osteotomy. *International journal of oral and maxillofacial surgery*. 2013 Sep 1;42(9):1083-92. <https://doi.org/10.1016/j.ijom.2013.04.001>.
14. Jones DL, Wolford LM. Intraoperative recording of trigeminal evoked potentials during orthognathic surgery. *The International journal of adult orthodontics and orthognathic surgery*. 1990 Jan 1;5(3):167-74. <https://pubmed.ncbi.nlm.nih.gov/2098452>.
15. Thomson S. Tooth Impacted in a Secondary Bronchus of the Left Lung; Removal by Lower Bronchoscopy after Two Unsuccessful Attempts by Upper Bronchoscopy. *The Boston Medical and Surgical Journal*. 1918 Nov 28;179(22):669-77. <https://doi.org/10.1056/nejm191811281792202>.
16. Keyhan SO, Khiabani K, Hemmat S, Varedi P. Zigzag genioplasty: a new technique for 3-dimensional reduction genioplasty. *British Journal of Oral and Maxillofacial Surgery*. 2013 Dec 1;51(8):e317-8. <https://doi.org/10.1016/j.bjoms.2013.01.013>.
17. Al-Ahmad HT, M Saleh MW, Hussein AU. Evaluation of an innovative computer-assisted sagittal split ramus osteotomy to reduce neurosensory alterations following orthognathic surgery: a pilot study. *The International Journal of Medical Robotics and Computer Assisted Surgery*. 2013 Jun;9(2):134-41. <https://doi.org/10.1002/rcs.1474>.