

Onychogryphosis nails in a diabetic patient: Rare Case Report



Seyed Mohammad Reza Amouzegar Zavareh^{1*}, Seyed Alireza Amouzegar Zavareh², Hooman Taghavi³, Faeze Baniyaghoobi⁴, Farshid Alazmani Noodeh⁵, Ali Moradi⁶

¹ Arthrosclerosis Research Center, Baqiyatallah University of Medical Sciences, Tehran, Iran.

² Kashan University of Medical Sciences, Kashan, Iran.

³ MSc Student of Nursing, Faculty of Nursing, Shahid Beheshti University of Medical Sciences, Tehran, Iran.

⁴ Instructor, Department of Military Nursing, Faculty of Nursing, Aja University of Medical Sciences, Tehran, Iran.

⁵ Assistant Professor, Department of Critical Care Nursing, Faculty of Nursing, AJA University of Medical Sciences, Tehran, Iran.

⁶ Students Research Committee, Nursing Faculty of Baqiyatallah University of Medical Sciences, Tehran, IRAN.

*Corresponding Author: Seyed Mohammad Reza Amouzegar Zavareh, Arthrosclerosis Research Center, Baqiyatallah University of Medical Sciences, Tehran, Iran. Email: amouzegar12@yahoo.com

Received 2023-01-31; Accepted 2023-08-22; Online Published 2023-09-01

Abstract

Onychogryphosis is a disorder caused by nail trauma. Although it may have an evolutionary cause, hitting and wearing tight shoes are significant factors. The patient was a 64-year-old man with a 20-year history of diabetes and coronary heart disease who presented to the wound clinic for a diabetic foot ulcer on his right foot. *Onychogryphosis*, also known as ram's horn nail, was diagnosed due to the high thickness, rotation, and downward twisting of the nail, resulting in a ram-like horn appearance. After disinfecting the fingers with an alcohol-free disinfectant spray, large and hard parts of the affected nails were removed using *Dual-action nail clippers*, and sharp edges and deformations were smoothed and sharpened using a *nail file machine*. Substantial nail improvement was observed after the procedure. Based on the photos taken after the procedure, the patient's nails were in good condition, and the patient was satisfied with the outcome. Appropriate foot health education was provided to the patient, and he was referred to an orthotics and prosthetics specialist to obtain suitable shoes.

Keywords: *Onychogryphosis*, *ram's horn nail*, trauma, diabetes.

Citation: Amouzegar Zavareh S-MR, Amouzegar Zavareh S-A, Taghavi H, Baniyaghoobi F, Alazmani Noodeh F, Moradi A. Onychogryphosis nails in a diabetic patient: Rare Case Report. Int J Travel Med Glob Health, 2023;11(3):320-323. doi: 10.30491/IJTMGH.2023.384027.1342.

Introduction

Onychogryphosis is a disorder caused by trauma to the nails. Although it may sometimes have an evolutionary cause, hitting and wearing tight shoes are important contributing factors. In such cases, the nails become thick, annular, and twisted in and out, resulting in a ram-like appearance that is referred to as "ram's horn nail". While this complication is not a disease in and of itself, it is primarily caused by aging, nail trauma, fungal infections, and certain conditions such as diabetes and peripheral vascular disease. *Onychogryphosis* was previously known as "horseshoe nails" because some cases were caused by a horse kicking the horseshoe leg while hoofing^{1,2}.

The condition identified as *onychogryphosis* is commonly observed among elderly individuals. A cross-sectional observational study found *onychogryphosis* to be present in 17.9% of 173 patients across three nursing

homes in Tokyo⁵. However, available reports on prevalence differ among some study groups, with rates ranging from 11.2%³ to 38%⁴. Nonetheless, all studies in this field agree that the majority of *Onychogryphosis* cases occur in the feet of the elderly³⁻⁵. Typically, the nails become thick and curved in such conditions, making them extremely hard to cut with conventional tools, resulting in the patient leaving them unattended. As a result, the nail grows longer, and more trauma is inflicted on it by wearing shoes.

Treatment is indicated for the prevention of complications and for cosmetic purposes⁶. The type of therapy recommended depends on the underlying cause of *onychogryphosis* and patient comorbidities and may involve either palliative or surgical management⁷. It is important to exercise caution to prevent undue pressure on the nail bed. Footwear should be thoroughly inspected to

ensure proper fit, with special emphasis placed on avoiding unnecessary pressure or microtrauma to the toes⁸. In the elderly population, conservative approaches are recommended, particularly in individuals with vascular impairment or hyperglycemia as a result of diabetes. Typically, the utilization of electric drills, burs, or mechanical debridement utilizing a dual-action nail nipper on a regular basis can assist in achieving and maintaining a reduction in nail plate thickness and length⁹⁻¹⁰. Prior application of cryotherapy to the nails can facilitate achieving a uniform edge during trimming¹¹. In this study, we aim to describe a patient with *onychogryphosis* who referred to JADA wound healing clinic (YARA WOUND CLINIC) for treatment.

Case report

The patient, a 64-year-old male, had a medical history of diabetes and coronary heart disease spanning over two decades. He had previously undergone angiography to improve his vascular status. The patient presented to the hospital with a diabetic foot ulcer on his right foot and provided informed consent prior to initiation of the study. Doppler ultrasound of the arteries in his right leg revealed adequate blood flow within his arteries, despite atherosclerotic vascular lesions. Following his discharge from the hospital, the patient sought further care at a wound clinic. During the initial examination, palpable pulses of the posterior tibialis and dorsalis pedis were noted but appeared to be weak. Antibiotics were prescribed due to an infection in his wound. The nail position of the patient's second toe of the left foot and fifth toe of the right foot captured the attention of wound therapists during the examination (see [Figures 2](#) and [1](#)). The patient was diagnosed with *Onychogryphosis* nails, commonly referred to as ram's horn nail, due to the high thickness, rotation, and twisting of the nail downwards, leading to the appearance of a ram-like horn. The occurrence of *Onychogryphosis* in the second and fifth toes in both feet is rare, as the condition typically presents in the first toe. To prevent the spread of *Onychogryphosis*, the fingers were disinfected with an alcohol-free disinfectant spray. The affected nails' large and hard parts were removed using Dual-action nail clippers (as shown in [Figure 3](#)), followed by sharpening and smoothing the sharp edges and deformations through the use of a nail file machine (as depicted in [Figure 4](#)). Notably, significant improvements in the condition of the nails were observed following the procedure, as evidenced by [Figures 5](#) and [6](#) ([Table 1](#)).

Table1: The results of the patient's paraclinical tests were as follows.

Test Name	Result	Flag	Unit	Normal Range
RBC	4.54	-	*10 ⁶ /micL	4-5.2
WBC	13.14	-	*10 ³ /micL	5-15
Hb A ₁ C	9.0	High	%	Normal: <5.7 Prediabetes: 5.7-6.4 Diabetes: >6.5
FBS	185	High	mg/dL	<100
ESR 1 st h	14	-	mm/h	0-15
CRP	Negative	-	mg/L	Negative
HDL	65	-	mg/dL	>=40
LDL	185	High	mg/dL	<130

Discussion

It is not an overstatement to assert that the majority of elderly patients suffer from stiffness and overgrowth of their nail matrix. Patients who frequent wound clinics report their inability to care for their thickened nails. In most cases, wound therapists are concerned about the possibility of the nail penetrating the skin or causing damage with its sharp edges to the fingertips, which can lead to new wounds in individuals with diabetes. It is peculiar to observe nails that twist and take on a ram's horn-like appearance instead of penetrating the skin and surrounding tissues. A cross-sectional study conducted in three nursing homes in Tokyo revealed that only 17.9% of 117 patients were affected by *Onychogryphosis*⁵. However, available reports on prevalence differ among some study groups, with rates ranging from 11.2%³ to 38%⁴. Nonetheless, all studies in this field agree that the majority of *Onychogryphosis* cases occur in the feet of the elderly³⁻⁵. Interestingly, in addition to persistent trauma throughout life (which causes acquired *Onychogryphosis*), *Onychogryphosis* appears to be genetically inherited as well. A rare case was reported of a two-year-old girl born prematurely who, after nail growth, showed hypertrophic nails that deviated to the side, leading to the identification of congenital *Onychogryphosis* for the first time¹². There have also been reports of *Onychogryphosis* as a symptom of several congenital syndromes, including *Papillon-Lefèvre syndrome*¹³, *Ichthyosis hystrix*¹⁴, and *type I ectodermal-syndactyly dysplasia syndrome*¹⁵.

Nails affected by *Onychogryphosis* can be difficult to manage depending on the patient's treatment goals. The etiology of this type of complication is due to continuous traumas resulting from wearing inappropriate shoes with poor foot hygiene^{7,16}, a problem commonly observed in

older individuals. The nail's growth is reversed, causing the nail plate to grow upward first and then pierce one of its two lateral fingers ^{17, 18}. In rare cases similar to that seen in our patient, the nail moves down and continues to grow instead of turning to the sides. During this deviation, the nail rotates like a ram's horn, hence the name. If the patient's nails are not removed completely, the complication may still occur due to poor personal care of the elderly, severe neuropathy common among them because of diabetes, and inability to perform routine foot hygiene, causing piercings on the toes. On the other hand, if the entire nail tissue is removed using the *Matrixectomy* procedure, re-growth of the nail on the toes is unlikely due to the loss of the germinal tissue of the nail, which may not be aesthetically pleasing for some patients ^{1,19}. However, some studies have concluded that complete removal of nail tissue is part of the definitive and necessary treatment process for *Onychogryphosis* ^{20, 21}. In our patient's case, we focused on maintaining the integrity of the nail according to his personal preferences. After explaining all the conditions, including the possibility of pathological nail regrowth, we proceeded with the described treatment process.

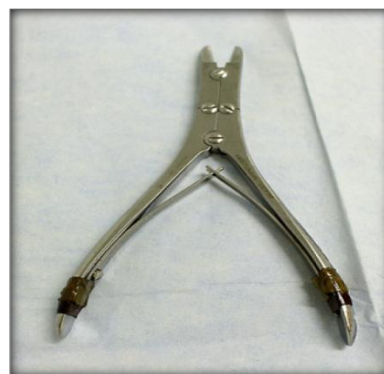

Figure 3: Dual-action nail clippers

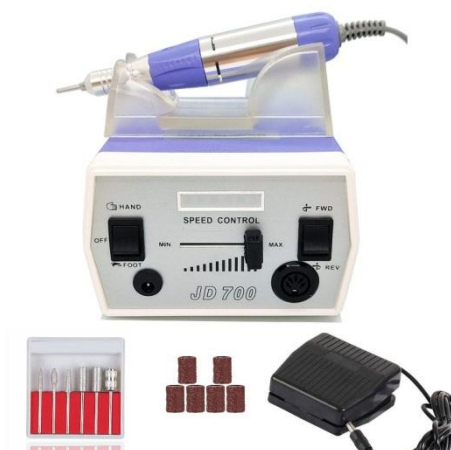

Figure 4: nail file machine

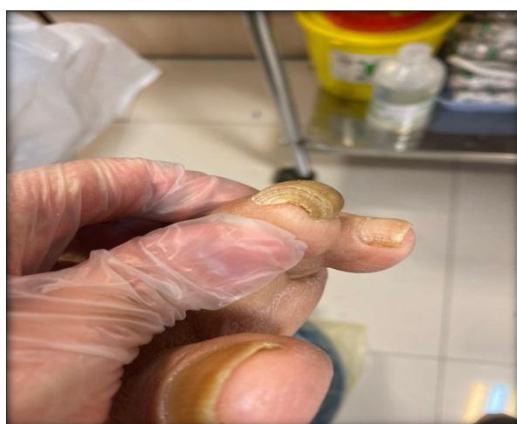

Figure 1: *Onychogryphosis* in second toe of left foot

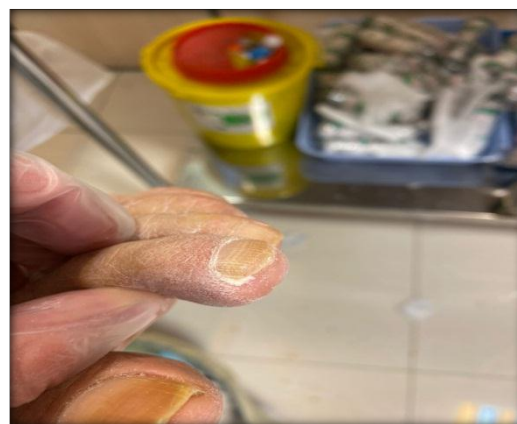


Figure 5: Treated nail, second toe of left foot

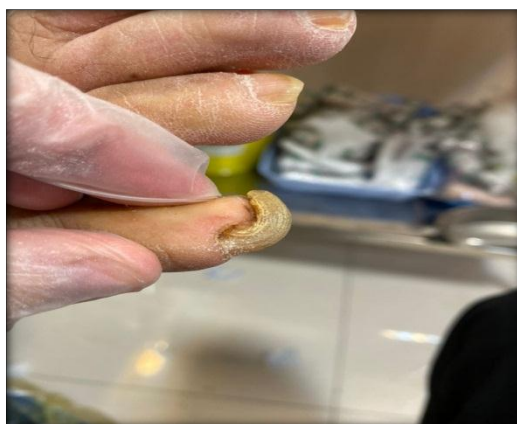

Figure 2: *Onychogryphosis* in fifth toe of right foot



Figure 6: Treated nail, fifth toe of right foot

Highlights**What Is Already Known?**

Nail trauma is a cause of Onychogryphosis disease. Although it may have an evolutionary reason, hitting and wearing tight shoes are significant characteristics.

What Does This Study Add?

Dual-action nail clippers are applicable to treat the nail, followed by sharpening and smoothing of the nail's sharp edges and deformities through a nail file machine.

Acknowledgments:

The authors are grateful to the participating patients and the officials of the relevant department.

Conflict of interest:

None declared

Authors' Contributions

Concept and design: Hooman Taghavi, Seyed Mohammad Reza Amouzegar Zavareh; Data gathering and preparing manuscript: Hooman Taghavi, Seyed Mohammad Reza Amouzegar Zavareh, Seyed Alireza Amouzegar Zavareh, Faeze Baniyaghoobi, Farshid Alazmani Noodeh, Ali Morad.

Consent For Publication

The authors have consent for publication.

Ethics approval

Not applicable.

Funding/Support

There is no funding for this study.

References:

- Galeone M, Scarfi F, Arunachalam M, Difonzo EM. Ram's horn nails. *Clin Exp Dermatol*. 2012;37(7):824. doi: [10.1111/j.1365-2230.2012.04367.x](https://doi.org/10.1111/j.1365-2230.2012.04367.x).
- Uva L, Lopes L, Filipe P. [Onychogryphosis]. *Acta Med Port*. 2014;27(4):531. PMID: 25203967.
- Zollinger H, Elsig JP, Jacob HA. [Foot problems in the elderly]. *Orthopade*. 1994;23(1):76-9. PMID: 7907780.
- Ebrahim SB, Sainsbury R, Watson S. Foot problems of the elderly: a hospital survey. *Br Med J (Clin Res Ed)*. 1981;283(6297):949-50. doi: [10.1136/bmj.283.6297.949](https://doi.org/10.1136/bmj.283.6297.949).
- Nakagami G, Takehara K, Kanazawa T, Miura Y, Nakamura T, Kawashima M, et al. The prevalence of skin eruptions and mycoses of the buttocks and feet in aged care facility residents: a cross-sectional study. *Arch Gerontol Geriatr*. 2014;58(2):201-4. doi: [10.1016/j.archger.2013.10.003](https://doi.org/10.1016/j.archger.2013.10.003).
- Singh G, Haneef NS, Uday A. Nail changes and disorders among the elderly. *Indian J Dermatol Venereol Leprol*. 2005;71(6):386-92. doi: [10.4103/0378-6323.18941](https://doi.org/10.4103/0378-6323.18941).
- Kouskoukis CE, Scher RK. Onychogryphosis. *J Dermatol Surg Oncol*. 1982;8(2):138-40. doi: [10.1111/j.1524-4725.1982.tb00251.x](https://doi.org/10.1111/j.1524-4725.1982.tb00251.x).
- Dermott RM KRCT. A case of onychogryphosis. *International Journal of Case Reports and Images*. 2012(3(1)):27-9. doi: [10.5348/ijcri-2012-01-86-CI-8](https://doi.org/10.5348/ijcri-2012-01-86-CI-8).
- Chelidze K, Lipner SR. In the Toolbox: The Dual Action Nail Clipper. *Dermatol Surg*. 2018;44(2):303-4. doi: [10.1097/DSS.0000000000001207](https://doi.org/10.1097/DSS.0000000000001207).
- Möhrenschlager M, Wicke-Wittenius K, Brockow K, Bruckbauer H, Ring J. Onychogryphosis in elderly persons: an indicator of long-standing poor nursing care? Report of one case and review of the literature. *Cutis*. 2001;68(3):233-5. PMID: 11579791.
- Yang TH, Tsai HH. Performing cryotherapy on onychogryphotic nails before nail trimming. *J Am Acad Dermatol*. 2016;75(2):e69-70. doi: [10.1016/j.jaad.2016.01.047](https://doi.org/10.1016/j.jaad.2016.01.047).
- Sequeira JH. Case of Congenital Onychogryphosis. *Proc R Soc Med*. 1923;16(Dermatol Sect):92. PMID: 19982897.
- Hattab FN, Amin WM. Papillon-Lefèvre syndrome with albinism: a review of the literature and report of 2 brothers. *Oral Surg Oral Med Oral Pathol Oral Radiol Endod*. 2005;100(6):709-16. doi: [10.1016/j.tripleo.2004.08.030](https://doi.org/10.1016/j.tripleo.2004.08.030).
- Biswas P, De A, Sendur S, Nag F, Saha A, Chatterjee G. A case of ichthyosis hystrix: unusual manifestation of this rare disease. *Indian J Dermatol*. 2014;59(1):82-4. doi: [10.4103/0019-5154.123512](https://doi.org/10.4103/0019-5154.123512).
- Mohammad A. Unusual manifestations of ectodermal dysplasia-syndactyly syndrome type I in two Yemeni siblings. *Dermatol Online J*. 2015;21(1). PMID: 25612123.
- Nath AK, Udayashankar C. Congenital onychogryphosis: Leaning Tower nail. *Dermatol Online J*. 2011;17(11):9. doi: [10.5070/D375n928bt](https://doi.org/10.5070/D375n928bt).
- Chang P, Meaux T. Onychogryphosis: A Report of Ten Cases. *Skinmed*. 2015;13(5):355-9. PMID: 26790505.
- Richert B, André J. Nail disorders in children: diagnosis and management. *Am J Clin Dermatol*. 2011;12(2):101-12. doi: [10.2165/11537110](https://doi.org/10.2165/11537110).
- Oka H, Asakage Y, Inagawa K, Moriguchi T, Hamasaki T. Free vascularized nail grafts for onychogryphosis of bilateral thumbnails after burn injury. *Burns*. 2002;28(3):273-5. doi: [10.1016/s0305-4179\(01\)00121-8](https://doi.org/10.1016/s0305-4179(01)00121-8).
- Kaplan I, Labandter H. Onychogryphosis treated with the CO2 surgical laser. *Br J Plast Surg*. 1976;29(1):102-3. doi: [10.1016/0007-1226\(76\)90104-1](https://doi.org/10.1016/0007-1226(76)90104-1).
- Kim SH, Ko HC, Oh CK, Kwon KS, Kim MB. Trichloroacetic acid matricectomy in the treatment of ingrowing toenails. *Dermatol Surg*. 2009;35(6):973-9. doi: [10.1111/j.1524-4725.2009.01165.x](https://doi.org/10.1111/j.1524-4725.2009.01165.x).