

Fever of unknown origin with final diagnosis of imported Malaria- A case study

Mohammad Javad Hoseini¹, Nematollah Joneidi Jafari^{*2}, Abbas Mahmoodzadeh Poornaki³, Javid Sadraei⁴, Babak Rezavand³, Aria Hamedanchi⁵, Jahangir Abdi⁶, Ozra Bagheri¹

Abstract

One of the most important infectious diseases in the world is *Malaria*. About half of the world populations are exposed to the risk of the disease. The program for controlling and eradication of *Malaria* has been being conducted in our country since many years ago.

One of the public health problems in the endemic and non-endemic countries is Imported *Malaria* which can cause new and permanent infected foci. Population movement and travelling from endemic areas can transmit the disease to the clean areas and can also transmit the drug resistant Protozoa particularly *Plasmodium Falciparum*.

Our case study describes a 30 year old person who has travelled to India for one month. He has visited a doctor in India because of fever, chills, malaise, and has received symptomatic treatment without any specific diagnosis. After returning to Iran, the symptoms appeared again after visiting by a doctor he has hospitalized with a diagnosis of Fever of unknown origin (FUO). He was checked for three days and on the fourth day, the blood smear of the patient showed *Plasmodium Vivax*. Ultimately he received the appropriate treatment and was discharged from the hospital in a good condition.

1. Molecular Biology Research Center, Baqiyatallah University of Medical Sciences, Tehran, Iran

2. Health Research Center, Baqiyatallah University of Medical Sciences, Tehran, Iran

3. Parasitology Department of Medical School, Zanjan University of Medical Sciences, Zanjan, Iran

4. Parasitology Department of Medical School, Tarbiat Modares University, Tehran, Iran

5. Zafaranieh Charity Infirmary, GP Technical Administrator Zafaranieh Charity Infirmary, Tehran, Iran

6. Department of Medical Parasitology, School of Paramedicine, Ilam University of Medical Sciences, Ilam, Iran

* Corresponding Author

DR.Nematollah Joneidi Jafari, Molecular Biology Research Center, Baqiyatallah University of Medical Sciences, Tehran, Iran
Email: Jonaidi2000@yahoo.com

Submission: 1 Aug 2013

Accepted: 3 Sep 2013

Key words: Imported Malaria, FUO, Plasmodium Vivax

Introduction

Malaria is an infectious disease which is caused by intracellular protozoa called Plasmodium. The disease can be transmitted by Female Anopheles mosquitoes. Each year 300 million people are infected which results in one million people deaths annually. It exists in over 100 countries in the world[1]. The children under 6 years old are more vulnerable to the disease. Three factors including infected person as reservoir, female anopheles mosquitoes, and normal person are involved in spreading of the disease, which can cause contamination in the clean area and make a new focus for the disease[2]. *Malaria* is a serious risk for the travelers and tourists to the endemic

parts of the world. In the case of being infected, they can transmit the disease to the clean areas[3]. In the countries which conduct the programs for controlling and eradication of *malaria*, Imported Malaria as a problem can hinder the progress of the programs. The model for controlling the imported *Malaria* is based on screening, treatment and combating the vectors [4-5].

Case presentation:

The patient, 30 years old, male, who is an art student, had travelled to India for one month after being invited by a scientific institute in 2011. He had also visited the different places during the travel. In his last days of staying in India, he got fever, chills, weakness, fatigue and headache. The



first evaluations in India had revealed no diagnostic finding and he was received symptomatic treatment. After returning to Iran, he went to a doctor again because of fever, chills, sweating, and headache. In outpatient examinations, no specific disease was diagnosed, and then the patient was hospitalized by an emergency room in Tehran, with a primary diagnosis of FUO. laboratory tests showed leukopenia, severe anemia, and low number of platelets. Ultimately on the fourth day of hospitalization and following the complementary tests, the blood smear showed *Plasmodium Vivax* (Figure 1). The treatment was applied according to the Health Minister protocol, and it was co-oriented with the state health centers. The treatment was started with Chloroquine and later Primakin was prescribed to continue and complete the treatment. The progress of disease indicated that it was a drug resistant form of falciparum or vivax. The response to the treatment was slow but finally the patient recovered and was discharged.

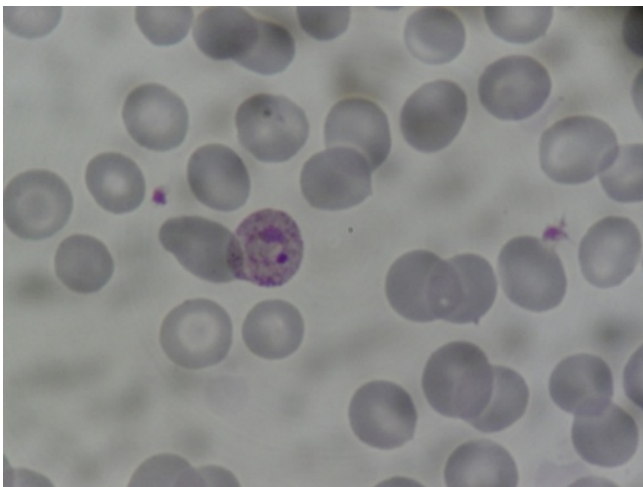


Figure 1. Plasmodium vivax ring-form trophozoites in thin blood smear

Discussion:

The first measure for eradication and uprooting malaria in Iran was started in 1947 and has continued until now and 8 types of Anopheles Mosquitoes have been identified in Iran which can cause permanent infections in the endemic foci[6].

According to the reports 85%-95% of malaria cases in the endemic south-eastern parts of Iran

are *Plasmodium vivax* and 10% -15% are *Plasmodium falciparum*. As a result of control programs, the disease is under control in the most areas of Iran and exists only in some parts of the following states: Sistan & Baluchestan, Hormozgan and Kerman [7]. At the present time, Iran is in the pre-elimination phase for controlling of malaria. Any new case of *Malaria* in unstable areas may cause unfavourable impact on controlling of the disease[8].

Furthermore, being in neighborhood of the countries such as Afghanistan, Pakistan and Iraq - which have slow progress programs for uprooting of malaria-has led to many Imported *Malaria* every year[9]. In our country there is no comprehensive consultation and awareness programs and dissemination of information for prevention of traveling diseases. So many people are infected through travelling to the area with endemic infection and later they seek for help from specialists of infectious diseases.

In the screening stage, that is vital to review diagnostic systems for malaria and also to apply rapid diagnostic molecular methods[10]. It is recommended to establish consultation centers for travelers' disease and to provide appropriate protocols. Dissemination of information among tourists and travel agencies and airlines can as well be useful for reducing the number of Imported *Malaria*.

Reference:

1. Garcia LS: Malaria. (1557-9832).
2. Boutin J, Pradines B, Pages F, Legros F, Rogier C, Migliani R: Epidemiology of malaria]. La Revue du praticien 2005, 55(8):833.
3. Wong CS, Behrens RH: Travel Health. Part 2: advising travellers visiting friends and relatives abroad. British journal of nursing 2008, 17(17):1099-1103.
4. Rey S, Zuza I, Martínez-Mondéjar B, Rubio JM, Merino FJ: Imported malaria in an area in southern Madrid, 2005-2008. Malaria journal 2010, 9(1):290.
5. Guedes S, Siikamäki H, Kantele A, Lyytikäinen O: Imported malaria in Finland 1995 to 2008: an overview of surveillance, travel trends, and antimalarial drug sales. Journal of travel medicine 2010, 17(6):400-404.
6. Edrissian GH: Malaria in Iran: Past and present situation. Iranian Journal of Parasitology 2006, 1(1).
7. Hassan V Fau - Arash R, Arash R Fau - Mehdi J, Mehdi J Fau - Ahmad R, Ahmad R Fau - Ali H-BA, Ali Hb Fau - Wali YA, Wali Ya Fau - Ali D, Ali D Fau - Abdulrasool M, Abdulrasool M Fau - Abbas P, Abbas P: Demonstration of malaria situation analysis, stratification and planning in Minab District, southern Iran. (1995-7645).

8. Hanafi-Bojd A, Vatandoost H, Oshaghi M, Eshraghian M, Haghdoost A, Abedi F, Zamani G, Sedaghat M, Rashidian A, Madani A: Knowledge, attitudes and practices regarding malaria control in an endemic area of southern Iran. *The Southeast Asian journal of tropical medicine and public health* 2011, 42(3):491.

9. Basseri H, Raeisi A, Holakouie K, Shanadeh K: Malaria prevention among afghan refugees in a malarious area,

southeastern Iran. *Bulletin de la Société de pathologie exotique* 2010, 103(5):340-345.

10. Nateghpour M, Khojasteh HA, Keshavarz H, Hajjaran H, Edrissian G, Rahimi A, Gobakhloo N: Comparison of microscopical examination and semi-nested multiplex polymerase chain reaction in diagnosis of *Plasmodium falciparum* and *P. vivax*. *Eastern Mediterranean health journal= La revue de santé de la Méditerranée orientale= al-Majallah al-ṣiḥḥīyah li-sharq al-mutawassiṭ* 2011, 17(1):51.

